



Department of Energy
National Nuclear Security Administration
Service Center
P. O. Box 5400
Albuquerque, NM 87185



September 19, 2008

SENT VIA E-MAIL
paulrubin713@comcast.net

Paul T. Rubin, M.D.
5646 Indigo Street
Houston, TX 77096-1125

Dear Dr. Rubin:

This letter is the final response to your August 1, 2008 Freedom of Information Act (FOIA) request for a copy of "The SL-1 Reactor Accident, Autopsy Procedures and Results" by C. C. Lushbaugh, D. F. Petersen, L. G. Chelius, T. L. Shipman, Published May 1961, Los Alamos Scientific Laboratory.

I contacted the Los Alamos Site Office (LASO) about your request. The Los Alamos National Laboratory retrieved the document from their research library and removed only the "Official Use Only" markings. We are providing the document to you in its entirety, as a .pdf file as you requested.

There are no fees chargeable to you for processing your request as you receive two hours of search and 100 pages free, and the fees are within what you receive free.

If you have questions please contact Ms. Karen Laney by telephone at (505) 845-5310, by e-mail at klaney@doeal.gov, or write to the address above. Please reference Control Number FOIA 08-235-K.

Sincerely,

Carolyn A. Becknell
Freedom of Information Act Officer
Office of Public Affairs

Enclosure

cc w/o enclosure:

Bonnie Wethington, LASO

J. R. Archuleta, IRM-RMMSO, IPO, MS-A150

LAMS-2550

LOS ALAMOS SCIENTIFIC LABORATORY
OF THE UNIVERSITY OF CALIFORNIA • LOS ALAMOS NEW MEXICO

THE SL-1 REACTOR ACCIDENT
AUTOPSY PROCEDURES AND RESULTS

SCANNED NOV 05 1998

LEGAL NOTICE

This report was prepared as an account of Government sponsored work. Neither the United States, nor the Commission, nor any person acting on behalf of the Commission:

A. Makes any warranty or representation, expressed or implied, with respect to the accuracy, completeness, or usefulness of the information contained in this report, or that the use of any information, apparatus, method, or process disclosed in this report may not infringe privately owned rights; or

B. Assumes any liabilities with respect to the use of, or for damages resulting from the use of any information, apparatus, method, or process disclosed in this report.

As used in the above, "person acting on behalf of the Commission" includes any employee or contractor of the Commission, or employee of such contractor, to the extent that such employee or contractor of the Commission, or employee of such contractor prepares, disseminates, or provides access to, any information pursuant to his employment or contract with the Commission, or his employment with such contractor.

LAMS-2550
BIOLOGY AND MEDICINE
Special Distribution

LOS ALAMOS SCIENTIFIC LABORATORY
OF THE UNIVERSITY OF CALIFORNIA LOS ALAMOS NEW MEXICO

REPORT WRITTEN: May 1961

REPORT DISTRIBUTED: June 21, 1961

THE SL-1 REACTOR ACCIDENT
AUTOPSY PROCEDURES AND RESULTS

by

C. C. Lushbaugh
D. F. Petersen
L. G. Chelius
T. L. Shipman

Contract W-7405-ENG. 36 with the U. S. Atomic Energy Commission

All LAMS reports are informal documents, usually prepared for a special purpose and primarily prepared for use within the Laboratory rather than for general distribution. This report has not been edited, reviewed, or verified for accuracy. All LAMS reports express the views of the authors as of the time they were written and do not necessarily reflect the opinions of the Los Alamos Scientific Laboratory or the final opinion of the authors on the subject.

CONTENTS

	Page
Chapter 1 Introduction	5
Chapter 2 Monitoring and Decontamination	8
Chapter 3 Autopsies	23
3.1 Autopsy Procedures	23
3.2 Autopsy Findings	25
3.2.1 RA-1	25
3.2.2 RA-2	32
3.2.3 RA-3	38
3.3 Histologic Findings	44
3.3.1 RA-1	44
3.3.2 RA-2	46
3.3.3 RA-3	46
3.4 Causes of Death	47
3.5 Biochemical Findings	49
3.6 Reconstruction of Positions of the Men at Time of the Accident	51
Chapter 4 Summary	57
References	61

TABLES

	Page
Table 1 The Effect of Various Thicknesses of Lead Shielding upon Dose Rate from RA-3 after Autopsy	21
Table 2 Total Gamma Radiation Exposure of Individuals during Entire Operation	22
Table 3 Neutron Dosimetry Based upon Radiochemical Phosphorus ³² Analyses of Hair Samples	50

ILLUSTRATIONS

Figure 1 Members of the autopsy team dressed to enter the decontamination area	12
Figure 2 Outline diagram of the topographical radiologic surveys of the 3 men before autopsy	16
Figure 3 Graphic summary of wounds of RA-1	27
Figure 4 Graphic summary of wounds of RA-2	34
Figure 5 Graphic summary of wounds of RA-3	41
Figure 6 Photomicrograph of a testicular tubule from RA-3	48
Figure 7 Mock-up of SL-1 reactor top used to position subjects in order to reconstruct the scene at the time of the accident	52
Figure 8 Simplest positions for all 3 men that seem to satisfy the requirements for causing their blast wounds	53
Figure 9 Simplest positions for all 3 men that seem to satisfy the requirements for causing their blast wounds at 90° counterclockwise from positions given in Fig. 8	54

CHAPTER 1

INTRODUCTION

At approximately 11:00 a.m. on the morning of Sunday, January 8, 1961, a telephone request was received at Los Alamos from the General Manager of the U. S. Atomic Energy Commission for us to send to Idaho Falls a pathologist and whatever supporting personnel would be required for the purpose of performing autopsies on the bodies of the 3 victims of the SL-1 reactor accident. A group of 8 men left Los Alamos in the Carco DC-3 at 2:30 p.m., arriving at Idaho Falls a little after 6:00 p.m. The members of the group were as follows: C. C. Lushbaugh, M.D., pathologist; D. F. Petersen, Ph.D., radiobiologist; Payne S. Harris, M.D.; Leo G. Chelius, M.S., in charge of health physics; James N. Lawrence, M.S., health physicist; Jerome E. Dummer, M.S., health physicist; Donald A. McKown, M.A., health physicist; and Morris J. Engelke, B.S., health physicist.

At Idaho Falls, the group was joined by Colonel S. W. Cavender (M.C.), Surgeon to the Field Command, Defense Atomic

Support Agency at Sandia Base, Albuquerque, New Mexico. Colonel Cavender, who had known the other members of the group for some years, became a full fledged and valuable member of the team.

Even in Los Alamos, the question was raised as to why the detailed post-mortem examination was called for. Probably the most compelling reason at the time was the hope that the autopsy procedure would effectively result in lowering the level of contamination of the 3 bodies to a point where they could be buried with reasonably normal methods. In addition, the bodies were so badly mutilated that complete assurance as to the identities seemed advisable; and it was also hoped that a careful study of the nature of the injuries would add to the rather scanty knowledge then available as to the cause of the accident and the activities of the men at the time it occurred.

All 3 of these, obviously, were gained; and, in addition, there was obtained invaluable experience which (a) indicated that autopsies can be performed on highly contaminated, highly radioactive bodies, and (b) enabled those participating to make recommendations as to procedures and equipment which would simplify such a procedure in the future.

The fact that the group was able to leave Los Alamos with no previous notice in a remarkably short time was due to the

existing emergency plan and to the fact that the majority of the supplies needed were already on hand and packaged for transportation.

The fact that the largest dose of radiation received by any member of the group was only 3.7 r seems extraordinary. Probably the factor which was most important in holding the exposure to a low level was the fact that the 5 health physicists were all men of long experience and unusual capabilities; furthermore, they and the other members of the team knew each other well and had worked together with them on many previous occasions. There existed the very necessary ingredient of mutual confidence and respect, which permitted things to get done with a minimum of hesitation and delay. Had a heterogeneous group of monitors been assembled from different installations, it seems almost certain that the operation could not have been carried out as effectively as it was. For any such operation in the future, therefore, it would seem advisable, if possible, to utilize a group of individuals who are familiar with each other's idiosyncrasies and who are accustomed to working as a team.

The autopsies were completed and the members of the group returned to Los Alamos on Friday, January 13, 1961.

CHAPTER 2

MONITORING AND DECONTAMINATION

Autopsies were performed on the 3 men who died in the reactor accident at Idaho Falls, contrary to the popular belief that necropsy examination is unnecessary and fruitless in cases of death from explosion. These examinations were made in order to identify the remains, prepare them for burial, establish the anatomical causes of death, and determine any pre-existing diseases, the character of the destructive forces and the spatial relationships of the men to them. In addition, since this was the first immediately fatal reactor accident where irradiation of the men did not appear to be a factor, a search was made for any information which might be helpful in understanding and investigating such injurious deaths in the future.

The bodies of the 3 men were removed from the reactor working area and transported to the room used for decontamination and autopsy by health physicists from the local

reactor testing site and Armed Forces personnel. The dead were designated as RA-1, RA-2, and RA-3, but identified as Richard L. McKinley, 27 years, Sp. 4, USA, trainee; John A. Byrnes, 22 years, Sp. 5, USA, certified SL-1 operator; and Richard C. Legg, 26 years, construction electrician-1, USN, certified SL-1 operator and crew supervisor. Identification was made at time of autopsy on the basis of height and body weight and dermal tattoos previously described in the health records. The time required to recover the bodies was 1-1/2 hours for RA-1, 24 hours for RA-2, and 5 days and 6 hours for RA-3. Until our decontamination and autopsy procedures were begun 6 days after the accident, the bodies of RA-1 and RA-2 were kept refrigerated in melting ice. No refrigeration could be done in the case of RA-3, who was at usual room temperature until his final removal to the autopsy room.

The published report (1) that "no autopsies were made" because "the force of the blast had blown radioactive particulate materials into the bodies," although erroneous, at least characterized the difficulty in handling, examining, and preparing the bodies for burial. Since bodies emanating such high levels of radioactivity had never been encountered previously, modifications of the usual autopsy procedures and techniques had to be improvised upon the basis of

radiologic safety procedures and common sense. National Bureau of Standards Handbook No. 65 (2) was not useful, since only millicuries of radioactive contamination are considered therein.

The personnel who made these examinations comprised a well trained team of 5 health physicists, 1 radiobiologist, 1 pathologist, and 2 physicians. This number of men was necessary because radiation levels in excess of 400 r/hr were encountered, and exposures had to be divided among the team in order to hold individual exposures to less than a 5 r total dose. Although the duties of the team members were dictated largely by their skills and the demands of each task, everyone except the pathologist aided in the chemical decontamination procedures. The health physicists were particularly responsible for radiologic surveying and monitoring of the area and personnel. They also obtained the necessary Polaroid photographs of the bodies. The physicians and radiobiologist were concerned principally with the performance of the autopsies and obtaining histologic specimens and specimens for chemical analysis. They also aided in the final decontamination through surgical excision of areas that could not be decontaminated further by chemical and mechanical means.

The decontamination facility was a room approximately 30 feet wide, 75 feet long, and 25 feet high. The outside exit was a roll-up door for motor vehicle entrance. Inside access was made by a standard door that opened into a hallway leading past a hot laboratory. The area of the hallway immediately outside the decontamination room was used to process personnel and material entering and leaving the decontamination facility. Protective clothing, respirators, radiation detection instruments, and plastic bags for disposal of contaminated clothing and equipment were stored here. The control cable of the overhead crane with a traversing bridge in the decontamination room was lengthened so that the crane could be operated from the hallway with the door closed.

All personnel entering the decontamination area wore 2 pairs of coveralls and 2 pairs of rubber boots. These were appropriately taped to prevent entrance of contamination. A surgeon's cap, full-face respirator with an ultradust filter, and 2 pairs of surgeon's gloves were also worn. Before entrance, a pair of slip-on plastic booties was put on over the outer boots (Fig. 1). When exit was made from the contaminated area, the outer pair of gloves and the plastic booties were discarded. A thorough survey was then made of the person, and any apparel found contaminated was discarded. Personnel performing the autopsies also wore




Fig. 1. Members of the autopsy team dressed to enter the decontamination area.

lead-impregnated rubber aprons weighing 45 pounds. Each individual entering the decontamination room wore a 200 mr and a 1.0 r direct reading pocket dosimeter to measure the current dosage. An Idaho Falls Operations Office film badge was also worn to measure the accumulated dosage and was the official record of dosage received during the operation. Occasional contamination of the inner clothing demanded this degree of protection. Airborne radioactivity was measured by a continuous air monitor in the hallway. Momentary opening of the door to the decontamination room doubled the background of the air monitor. Negative results, on final survey of all personnel in the Los Alamos Human Counter, and negative urinalyses indicated that the protection afforded by these methods against airborne contamination had been adequate.

The general radiation background in the room with the bodies was less than 0.01 mr/hr. All measurements made on surveys were gamma readings with Jordan Radectors, which could measure a maximum dose rate of 500 r/hr. Isolated spots on the absorbent paper covering the stainless steel floor read up to 4 r/hr. The radiation reading in front of the sink holding the 2 bodies behind a portable 1/4 in. lead shield fastened to the crane hook was 0.8 r/hr.

An initial survey disclosed that the 2 bodies in the

sink were covered with ice except for an exposed shoulder (reading 6.5 r/hr) and a leg (reading 40 r/hr). After the ice was melted with warm water, 1 body (RA-2) was removed from the sink and placed in a partially shielded stainless steel tank about 10 feet away. A rough survey on this body indicated that the highest radiation level was below the left knee, which measured 200 r/hr with a general background of 10 r/hr over the rest of the body. The radiation level through the shielding tank in which the body was placed was 3 r/hr.

A thorough survey was then made of the body (RA-1) remaining in the tank. The highest reading was 150 r/hr on the left hand with a general background of 5 to 6 r/hr over the rest of the body. Attempts were then made to decontaminate this body. Various detergents, ethylenediamine tetraacetate (EDTA), and citric acid were used, and the body was vigorously scrubbed with long-handled brushes. Care was taken to prevent spread of contamination from the areas of highest concentration. The body was then flushed with clean water. A sling was placed under the shoulders, and the body was moved by crane to an improvised autopsy table made by putting a shallow stainless steel tray (approximately 6 feet by 2-1/2 feet) on 2 saw horses. Another survey was then made of this body, which showed the left hand to read 100 r/hr, the left shoulder 6 r/hr,

top of head 5 r/hr, hair on back of head 25 r/hr, right side of head 6 r/hr, right shoulder 3 r/hr, right hand 2 r/hr, right side of abdomen 3 r/hr, pubic region 5 r/hr, left of pubic region 4 r/hr, right leg above knee 2 r/hr, left leg above knee 4 r/hr, and the feet 1 r/hr (Fig. 2). Surgical removal of the shredded fragments of the left hand and fractured ulna reduced these radiation levels 1 to 2 r.

The autopsy on this man was then performed. After its completion, the tissue specimens and those for chemical analysis were packaged and appropriately stored. A survey of the body now indicated a high reading of 4 r/hr with a general background of 2 r/hr and a minimum of 1 r/hr on the feet. The body was wrapped in a double thickness of heavy plastic sheeting and placed in a deep freeze box to await embalming.

RA-2 was then transferred from the shielded tank to the sink. A survey on this individual indicated that the highest level was 200 r/hr located on the severely fractured left foot. Additional hot spots were hair 50 r/hr, gash on left side of head 40 r/hr, gash below right knee 50 r/hr, above left knee 50 r/hr, and pubic region 15 r/hr. The balance of the body read from 2 to 10 r/hr. Further decontamination attempts on this body were relatively unsuccessful. Most of the contamination, as on the first body, was embedded in

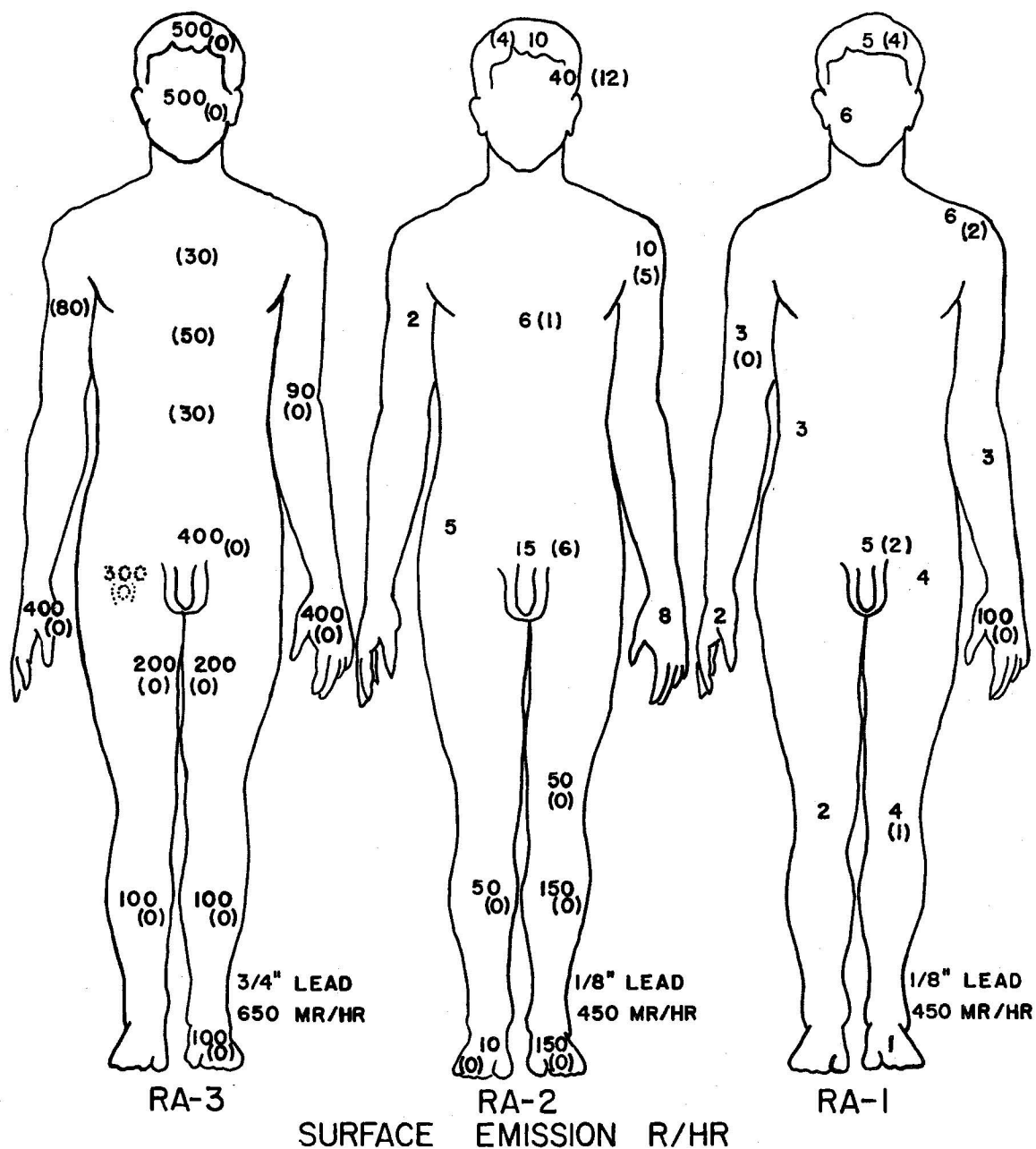


Fig. 2. Outline diagram of the topographical radiologic surveys of the 3 men before autopsy. The figures are r/hr at the surface, and the figures in parentheses are the readings after autopsy, debridement, and shaving. Final radioactivity after shielding with lead is indicated along the side of the left foot of each man.

blast wounds. The body was next transferred to the table, where surgical completion of the avulsion, dislocation, and fracture of the right knee and the compound fracture and blast wound of the left thigh allowed removal of these excessively radioactive areas so that the autopsy could be done. After its completion, the body was wrapped in a plastic sheet and stored in the deep freeze. The final readings on RA-2 were head region 4 r/hr, left shoulder 2 r/hr, left wrist 3 r/hr, chest region 3 r/hr, pubic area 2 r/hr, and legs 1 r/hr.

In preparation for the work on RA-3, the sink drain strainer (reading about 100 r/hr) was discarded and a new one installed. The drain was protected by heavy wire screen weighted with lead bricks to avoid plugging. The absorbent paper floor covering was replaced. The body was brought into the decontamination facility in a lead cask on a semi-trailer truck, which was brought to a location near the sink. The cask was about 6 feet long, 5 feet wide, and 5 feet high, with 4 in. thick walls and bottom. Radiation levels around its outside ranged from 100 to 300 mr/hr. Levels in the cask about 15 in. from the body ranged from 100 to 200 r/hr. A tarpaulin wrapped around the body was heavily contaminated with loose material. Airborne activity was high during the period when it was folded back to expose the body and to

retrieve the loose end of a rope sling previously placed about the body. Loose material was flushed off the body by a spray of warm water. The body was then completely covered with water and soaked overnight.

The next morning (9 days after the accident), the tank was drained and the body again flushed with water. Dose rates were now 50 to 60 r/hr over the north edge of the drained cask and 500 r/hr 5 in. from the body's head. It was estimated that a contact measurement at the head would have been about 1500 r/hr. The drain in the tank was then closed, the tank filled with an aqueous solution of detergent and EDTA, and the body soaked for 2 hours. The body was attached to the crane by the rope sling and agitated in the bath by repeatedly raising and lowering. A measurement of 400 r/hr was then obtained from the region of the head, indicating that some reduction in level had been achieved. The tank was again drained and the body flushed with a spray of water. Another survey at this time indicated that no further reduction in radiation levels was being obtained. The body was then raised by the crane out of the tank and Polaroid photographs taken. Inspection of these photographs revealed that the bulk of the man's clothing was still on him and that his head, which appeared to be the major source of the prohibitive radiation level, had been damaged by the

blast beyond recognition. The calvarium and scalp hung to it by a thin skin flap. There could be seen some obvious cervical fractures, which appeared to make feasible the separation of the head from the body by rapid, sharp dissection. This operation was then carried out with specially prepared knives, long-handled hooks, and a wire snare controlled through a 10 foot pipe handle. The remains of the head were placed in a lead cave 20 feet from the cask. The body was then suspended above the cask by the crane and the clothing removed from it by the long-handled knives and hooks. These instruments, which were manufactured from hack saw blades, iron rod, and pipe in the local welding shop,* enabled the autopsy personnel to remove all clothing and to make the early autopsy dissection of this body from a distance sufficient to keep radiation exposure to a remarkable minimum.

The body was next moved to the sink by means of the overhead crane and a complete survey made. At the feet, the reading was 100 r/hr, near burns along the inside of the legs 200 r/hr, in the pubic region 400 r/hr, a hand 400 r/hr, and midway between this hand and shoulder 90 r/hr. A general reading 1 foot above the body was 50 r/hr. Outside the sink,

*Phillips Petroleum Company.

the dose rate varied from 10 to 300 r/hr. Sheet lead (1/4 in. thick) was hung from the crane and positioned at the point of highest dose rate in front of the sink. Another attempt to reduce contamination by scrubbing with detergent solution was unsuccessful.

The autopsy was now performed with the body in the sink by pathologist and assistant using the portable lead shield whenever possible. After inspecting the body closely, the wounded legs and hands were removed and placed in the shielded tank 10 feet from the sink. This debridement and the subsequent autopsy took 18 minutes, and the doses were 3 and 2.7 r to the pathologist and assistant, respectively, as measured by their pocket dosimeters. A final decontamination attempt was then made using detergent solution. The post autopsy survey showed lower lumbar region 30 r/hr, chest region 50 r/hr, and near a wound on the arm 80 r/hr. The body, like the others, was packaged in plastic and removed to the deep freeze.

Some crude measurements were made at this time to determine the effectiveness of lead shielding on the third body. These measurements are summarized in Table 1.

The usual decontamination procedures were not very effective on the bodies. Washing and scrubbing were effective only in areas of unbroken tissue and then only to a

TABLE 1. THE EFFECT OF VARIOUS THICKNESSES OF LEAD SHIELDING
UPON DOSE RATE FROM RA-3 AFTER AUTOPSY

Lead Shielding (in.)	Dose Rate (r/hr)*
0	40.0
1/8	7.0
1/4	5.0
3/8	3.5
1/2	2.4
5/8	1.9
3/4	1.7
1-1/8	1.0
1-1/8 (18 in. from shield)	0.5

*The general background during these measurements was
0.25 r/hr.

limited extent. In areas of trauma from blast, the only effective method of decontamination was found to be the removal of tissue.

The remainder of the work in the decontamination facility consisted of recovery and packaging of autopsy samples and cleaning up of the highly radioactive waste material. Samples were placed in suitably shielded shipping containers. The waste was placed in drums which were removed to the radioactive disposal ground on the low-boy truck.

The individual total gamma exposures to the autopsy team, as determined by film badge (IDFOO), are given in Table 2.

TABLE 2. TOTAL GAMMA RADIATION EXPOSURE OF INDIVIDUALS DURING ENTIRE OPERATION

Personnel	Dose (mr)
Pathologist	3265
Assistant No. 1	2645
Assistant No. 2	3680
Assistant No. 3	900*
Health Physicist No. 1	2405
Health Physicist No. 2	2325
Health Physicist No. 3	2230
Health Physicist No. 4	2345
Health Physicist No. 5	1430

*In attendance during first 2 autopsies only.

CHAPTER 3

AUTOPSIES

3.1 Autopsy Procedures

Although no actually new techniques were used in the autopsies, ordinary methods of dissection were modified by the use of disposable knives and hooks that had 4 to 5 foot long handles and made of 3/8 in. galvanized pipe. The tools themselves were fabricated in the local shop from 1-1/2 in. wide hack saw blades, metal rod, and pipe. The blades sharpened well but were brittle and could not withstand strong pressure. A Stryker "cast-cutter" electric autopsy saw and a heavy duty electric hair clipper were also used. Even though all these tools had to be discarded because of heavy contamination by radioactive materials, their use was justified because of the time and consequent exposure they saved.

The time involved in the customary inspection of the bodies was reduced to verification of lesions, tattoos, and

missing parts already observed in Polaroid photographs of the bodies obtained in the course of chemical decontamination and radiologic surveys. These photographs enabled the pathologist to make accurate and complete external descriptions without unnecessary exposure to radioactivity. They were also used to record topographically the results of the radiologic surveys and to plan procedures for each specific case (Fig. 2).

In each case, surgical decontamination was done first by sharp dissection of distal fragmented blast wounds that were heavily contaminated and highly radioactive. In the case of RA-1, this procedure consisted of the removal of the distal fragment of the left ulna and hand at the distal head of the radius. With RA-2, the dislocation and avulsion of the right knee and the compound fracture of the middle right femur were completed. In each of these cases, this surgical debridement along with removal of all the hair from the head, axillae, and pubis by electric clipper reduced the surface radioactivity to comparatively safe levels so that the viscera and brain could be removed in the usual manner and the thoracic, abdominal, and cranial cavities inspected closely.

In the case of RA-3, even after surgical debridement, surface radioactivity was still sufficiently high to require the pathologist to open the body with the long-handled

instruments and inspect and remove the viscera from behind the suspended lead shield previously described. All the viscera were dissected about 30 feet away from the location of the bodies. In each case, the actual autopsy required from 15 to 20 minutes. Autopsy specimens were fixed in 10 per cent neutral formalin for histologic study and quick frozen for chemical analysis.

3.2 Autopsy Findings

3.2.1 RA-1

External Appearance. The body was that of a young male adult. He was small, being less than 5 feet, 6 in., in height. He weighed approximately 115 pounds but was well developed. There were numerous evidences externally of blast injury. The head, which was covered by short brown hair, had a semicircular sharp wound over the vortex which penetrated the complete thickness of the scalp. The right lower quadrant of the face had been partially destroyed by a penetrating and avulsing wound, which caused a destructive fracture of the right maxilla, the inferior edge of the right orbit, and fracture of the right mandibular joint. Both eyeballs were flattened and contained no fluid. The skin over this wounded area of the right cheek (approximately 10 by 10 cm) was missing, and the skin of the nose had been blown

upward and outward so that the right nasal cavity could be visualized. The left side of the face, neck, and chest were a diffuse dusky violet. There was obvious subcutaneous hemorrhage. This area showed many bruises and punctate, irregular superficial cuts, which penetrated only through the full thickness of the skin. These cuts measured up to 2 cm in length. There was no gross abnormality of the chest and the right upper extremity. The left arm was normal except for the left hand, which was shredded. Only the thumb and first and second fingers were present; the palm was completely destroyed by avulsion, and the tendons hung loosely. The left forearm was split up to its midpoint where there was a comminuted compound fracture of the ulna. The genitalia were normal in appearance. The scrotal and pubic hair was abundant. The left lower extremity showed numerous punctate lacerations and wounds surrounded by hemorrhage in the subcutaneous tissues. These were most numerous over the left upper thigh and left lower leg. The right leg was free of wounds, as were the right arm and hand. The back showed only post-mortem lividity. These wounds are summarized graphically in Fig. 3.

Abdominal Cavity. Fat in the midline averaged 1 cm in thickness. The peritoneal surfaces were smooth and glistening. The margins of the liver were at the costal margins.

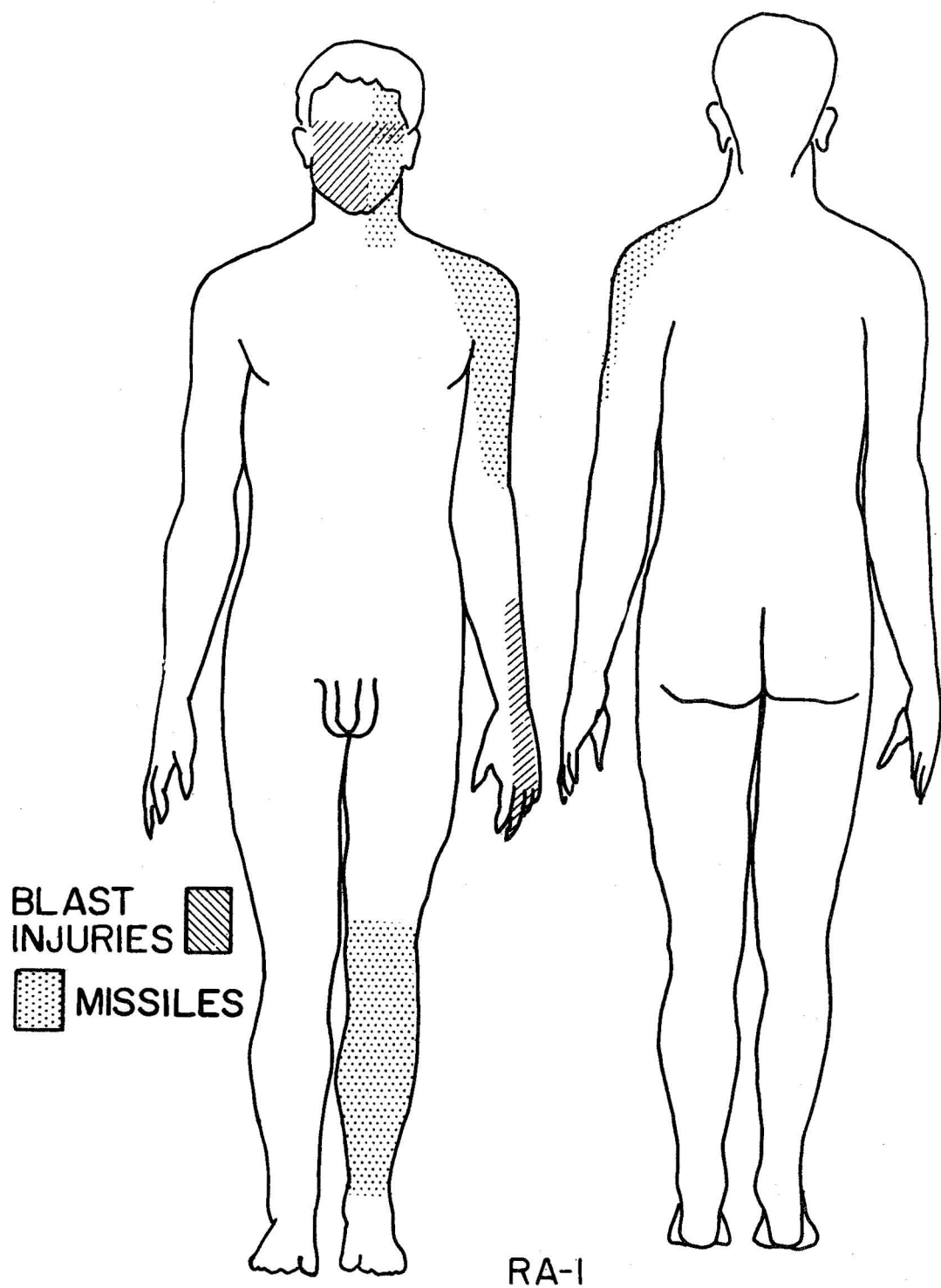


Fig. 3. Graphic summary of wounds of RA-1.

The spleen could not be seen. The organs had their proper relationship to one another. The diaphragms were at the fifth rib on both sides.

Pleural Cavities. The right pleural cavity was normally moist and glistening. The left pleural cavity contained blood, which appeared to have emanated from a trocar wound made post mortem in the left lower lobe and heart in order to obtain a blood sample. The left intercostal muscles between the first and fourth ribs were diffusely hemorrhagic. The left pectoralis major muscle had hemorrhage in it and in the overlying subcutaneous tissues. The ribs, however, were not broken.

Pericardium. The pericardium contained some blood, which appeared to have stemmed from the post-mortem blood sampling procedure.

Oral Mucous Membranes. The oral membranes contained fresh hemorrhage. They were otherwise pale.

Thyroid and Thymus. The thyroid gland was normal in size and shape. The thymus was a dusky red, noninvolted glandular organ. It was estimated to weigh approximately 50 grams.

Trachea and Main Bronchi. The trachea and main bronchi were surrounded by normal appearing connective tissues free from hemorrhage. Their mucosa was hyperemic and contained

a small amount of blood aspirated from the oral cavity.

Tracheobronchial Lymph Nodes. The tracheobronchial lymph nodes were large in size but free from tuberculosis or calcification. They were unusually anthracotic and fleshy.

Lungs. The left lung weighed 650 grams. There was a hemorrhagic consolidation of almost the entire upper lobe, which was most noticeable posteriorly. There was no evidence of a penetrating wound of this lobe. The left lower lobe had a post-mortem trocar wound in it. It was slightly increased in weight because of edema and scattered petechial hemorrhages under the pleura. The right lung weighed 550 grams. It had scattered hemorrhages and edema throughout but had no hemorrhagic consolidation.

Heart. The emptied heart weighed about 300 grams. It had 3 post-mortem trocar wounds in it, 2 in the left ventricle and 1 in the base of the right ventricle. The valves and valve rings were normal. The pericardium was smooth and glistening. The muscle was dark red and free of abnormalities. The coronary arteries were patent throughout.

Liver. The liver weighed an estimated 1200 grams. The capsule was thin and transparent. The parenchyma was dark brown. There were no hemorrhagic areas in it. The gallbladder was normal in size and appearance. There was post-mortem diffusion of bile from it.

Spleen. The spleen weighed 110 grams. It was flabby and the cut surface showed dark reddish soft pulp in which follicles could not be seen.

Pancreas. The pancreas appeared to show post-mortem digestion.

Gastrointestinal Tract. The duodenum was opened and a generalized loss of mucosa and a diffuse reddening were found. These changes appeared due to severe post-mortem digestion. The stomach contained 300 cc of thick green fluid. There was no abnormality of the small or large intestine.

Adrenal Glands. Both adrenal glands were normal in size and shape. Their cortices were lipid-rich but thin. There was post-mortem autolysis of the medullae.

Kidneys. The left kidney weighed 100 grams, the right 105 grams. The capsules stripped easily. There were no abnormalities of the cut surfaces which were, however, pale.

Urinary Tract. The ureters and urinary bladder were normal. The urinary bladder contained 100 cc of clear, yellow urine. The prostate was normal in size and shape. The testes were grossly normal in appearance and appeared to be uninjured.

Bone Marrow. The bone marrow in the vertebral bodies appeared to be quite diffluent and soft.

Brain and Meninges. When the scalp was reflected, it was found that underneath the semicircular laceration of the scalp there was diffuse bleeding into the subcutaneous tissues, indicative of this person's survival for a short time after the accident. There was no fracture of the skull under this wound. When the calvarium was removed, however, the surface of both hemispheres and the falx were found covered by about 50 ml of subdural hemorrhage. The brain was hyperemic and lavender. It was estimated to weigh about 1500 grams. There was no obvious tear in it. The pituitary gland could not be found after the brain was removed.

Gross Anatomical Diagnosis. Multiple blast injuries consisted of avulsion of the right face and left hand with loss of left third, fourth, and fifth metacarpal and phalangeal bones; fractures of right mandible, right maxilla, right inferior orbital ridge, right nasal bone, and left ulna; rupture of both orbs (massive hemorrhage from blasted face and left hand); multiple lacerations of the scalp, left face, neck, shoulder, and left leg; hemorrhagic suggillations of the scalp, left pectoral and intercostal muscles; diffuse subdural hemorrhage; aspiration of oral pharyngeal hemorrhage; persistent thymus; and probable active pneumoconiosis, anthracotic type with hilar lymph node hyperplasia.

3.2.2 RA-2

External Appearance. The body was that of a young male adult measuring about 5 feet, 10 in., and weighing about 175 pounds. The hair of the head was blond and crewcut. There was a 10 cm long dirty gash in the left temporal area of the scalp. Two quite noticeable tattoos were present on the right arm; on the inner aspect, there was a flowery tattoo with the word "Jack" in its middle, and on the lateral surface there was an enscrolled red heart. The facial surface had been blown inward, but there were only superficial lacerations of the skin in this area. There was a central fracture of the maxilla and the inferior orbital ridges. Both eyeballs were collapsed. There were also fractures of the right mandibular joint and the right side of the mandible. Multiple teeth had been broken loose, particularly the central incisors. While the right arm and both hands were uninjured, the left arm had been severely damaged. The central portion of the left humerus was the site of a comminuted fracture. The whole humerus had been shortened without breaking the skin to about half its length. The arm appeared to have been wound about this area once and then to have been unwound. The left forearm showed severe lacerations posteriorly, but the hand was undamaged. The thorax was severely deformed. There were multiple fractures of the

ribs, which could be felt from the outside of the chest. The left upper part of the chest was unusually prominent, while the lower part of the chest had been caved in. There was diffuse subcutaneous hemorrhage of the entire frontal aspect of the chest. The abdomen appeared unaffected. The genitalia were normal. The lower extremities showed severe blast injury to the posterior of both legs. The right popliteal fossa was completely destroyed, and the right knee had been dislocated forward so that it hung by the skin and patellar ligaments. The lower half of the left leg was partially missing, and ragged shreds of skin and muscle hung from the fractured tibia. There was a compound fracture of the left femur about midway between hip and knee. The wound here was posterior and comprised an avulsion of the left gluteus and quadriceps muscles. The severity of this blast injury dissipated as it spread to destruction and loss of tissue of the right buttocks and lower back, but the entire pelvis had been fractured, the sacrum thrust into the true pelvis, and the pubic symphysis separated. These injuries are summarized graphically in Fig. 4.

Abdominal Cavity. The abdominal cavity contained blood. There was hemorrhage particularly around the splenic fossa and pelvis. The spleen was partially torn from its pedicle and its capsule ruptured, but it was still hanging by the

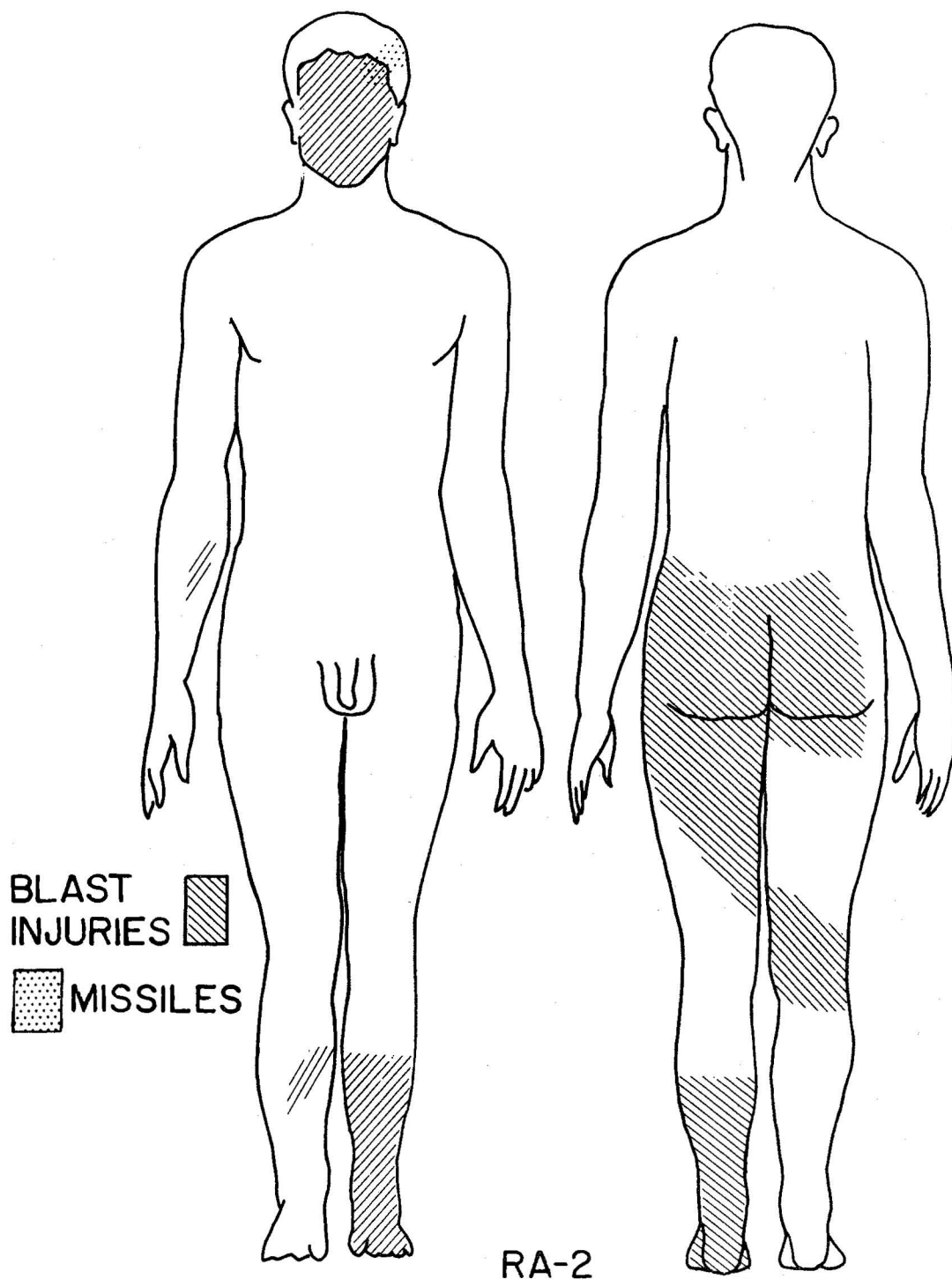


Fig. 4. Graphic summary of wounds of RA-2.

splenic artery. The right kidney had been stripped from its capsule posteriorly and also had its veins torn at the pelvis so that there was a massive retroperitoneal hemorrhage on this side. There was similar hemorrhage in the pelvis underneath the peritoneum in the region of the sacral fractures. There was gaseous dissection of the peritoneum around the torn urinary bladder. The pubic symphysis was found separated 3 cm. The comminuted sacral bones were moved into the lower pelvis without rupture of the peritoneum and muscles. The sacrum appeared to have been separated from the rest of the vertebral column in the blast.

Pleural Cavities. The ribs on the right were fractured down to the eighth rib. The ribs on the left were fractured down to the tenth rib. The floating ribs on each side were intact. The left third, fourth, fifth, and sixth ribs had been fractured twice. The fifth rib was driven through the pericardium into the heart. There was massive pericardial hemorrhage and hemorrhage into the left pleural space. The subcutaneous tissues over the entire chest were hemorrhagic. There was severe hemorrhage of the mediastinal structures with massive hemorrhage around the trachea and main bronchi.

Oral and Pharyngeal Mucous Membranes. These were covered by blood.

Thymus. The thymus was present as a solid gland surrounded by hemorrhage.

Trachea and Main Bronchi. The trachea and main bronchi were surrounded by hemorrhage in their loose areolar tissues.

Lymph Nodes. The lymph nodes were anthracotic but normal in appearance.

Lungs. Each lung weighed 500 grams. They contained diffuse petechial hemorrhages but no other gross abnormalities except pleural surfaces covered with blood.

Heart, Aorta, and Great Vessels. The heart weighed approximately 350 grams. There was a jagged penetration wound of the conus of the aorta just below the aortic valve ring. This laceration entered the left ventricle and then penetrated the interventricular septum 4 cm below the base of the heart or midway between the base and apex. There was a moderate left myocardial hypertrophy. The valves and valve rings were normal.

Liver. The liver weighed 1800 grams. Its capsule was thin, and the parenchyma was dark brown. The gallbladder showed severe post-mortem staining of the surrounding peritoneum.

Spleen. The spleen weighed approximately 120 grams. Its capsule was torn, and there was clotted blood in the torn tissue of its hilum.

Pancreas. The pancreas showed severe post-mortem digestion.

Gastrointestinal Tract. There was no obvious abnormality of the entire gastrointestinal tract. The stomach contained about 300 cc of fluid material. No attempt was made to examine it or the contents of the small or large intestine. A small amount of feces was present in the descending colon and rectum.

Adrenal Glands. Both adrenal glands were normal in size and shape. There was post-mortem autolysis of the medulla. The lipid-rich cortex measured about 1 mm in thickness.

Kidneys. The right kidney had already been stripped of its capsule. There was hemorrhage around its pelvis and around the major blood vessels. The parenchyma was extremely pale, as is often the case in exsanguination. The cortical medullary markings in both kidneys were normal.

Genitourinary Tract. The ureters and urinary bladder were normal in appearance. The urinary bladder was devoid of urine.

Prostate. The prostate was normal in size and shape.

Testes. The testes were normal in size, shape, and consistency.

Brain and Meninges. The brain was normal in size. The

gyri and sulci of the cerebral cortex were covered by a thin (up to 4 mm in thickness) layer of blood which was present over the convexity, as well as the base. There was no evidence of cranial fractures or tears in the dura. The pituitary was removed successfully.

Gross Anatomical Diagnosis. Severe blast injuries consisted of avulsion of the muscles and soft tissues of the left buttocks, lower back, upper left thigh, left lower leg, and right popliteal space; fractures of the facial bones, left midhumerus, left midfemur, lower left leg and foot, sacrum, ischial bones, and pubis; dislocation of right knee; rupture of both optic orbs; and gaseous dissection of pelvis retroperitoneum. Severe crushing injuries consisted of multiple fractures of the ribs (right 1 through 6 and left 1 through 10) with compression of the left lower chest, penetrating myocardial stab wound by left fifth rib, and massive pericardial, mediastinal, and pleural hemorrhage; massive subcutaneous and intramuscular hemorrhage of the anterior thorax; splenic and left renal rupture with massive upper abdominal hemorrhage; diffuse subdural hemorrhage; persistent thymus; and tattoos of right forearm.

3.2.3 RA-3

External Appearance. The body was that of a young adult male about 5 feet, 6 in., in height and weighing about

160 pounds. His body was well muscled but had been severely injured by blast so that both feet dangled from the legs by shreds of skin. The left leg was almost completely severed from the body by a shearing, destructive force which completely destroyed the left hip joint and the left side of the pelvis, and dissected the skin of the left side of the body up to the level of the umbilicus, where a band approximately 20 cm wide of full skin thickness held this leg to the body. There was a wound roughly 20 cm in length located to the left of the pubis, which entered the abdominal cavity through the inguinal insertion of the abdominal muscles. About 10 feet of mesentery and intestine protruded from this wound. The external genitalia were not injured. The inner aspects of both thighs showed reddish, dark blue to purple areas, which appeared typical of superficial flash burns. The right femur had a fracture in it about 15 cm below its surgical neck. There were tears in the buttocks posteriorly, although this leg was not torn quite so extensively from the body as the left one. The wrists had similar tears in them so that both wrists were partially torn away and the hands dangled from the arms. The hands were dark blue and appeared also to have been injured by heat. The face had been flattened. The eyes had been ruptured. The nose, maxillary bones, and lower jaw had all been pushed back into the neck

and base of the skull. The calvarium was severed cleanly, as if by a cheese knife, from the rest of the skull. The calvarium had a similarly sized piece of scalp with dark brown hair attached to it. The brain was soft and showed severe post-mortem autolysis. It appeared severely torn although still recognizable. There was a tattoo of a letter "C" and a bumblebee on the right shoulder, and on the skin of the inner aspect of the left forearm a 20 cm long dancing sailor girl was tattooed. The upper half of the torso was twisted 180° around to the right so that the left shoulder and scapula were in the position of the right shoulder. The right shoulder occupied the similar position of the left shoulder. This twist occurred in the vertebral column in the first and second lumbar segments, which were also compressed. These injuries are summarized graphically in Fig. 5.

Abdominal and Pleural Cavities. The abdominal and pleural cavities were single because the diaphragm was torn and partially missing. This cavity communicated with the outside through a 20 cm tear in the lower abdominal wall and pelvic floor. The lungs, heart, and mediastinum were torn from their attachments and were free in the pleural space. The lungs were collapsed. The liver was lacerated and only about one-half of it was recognizable. It was dark red, in general, but had areas that appeared cooked. The intestines

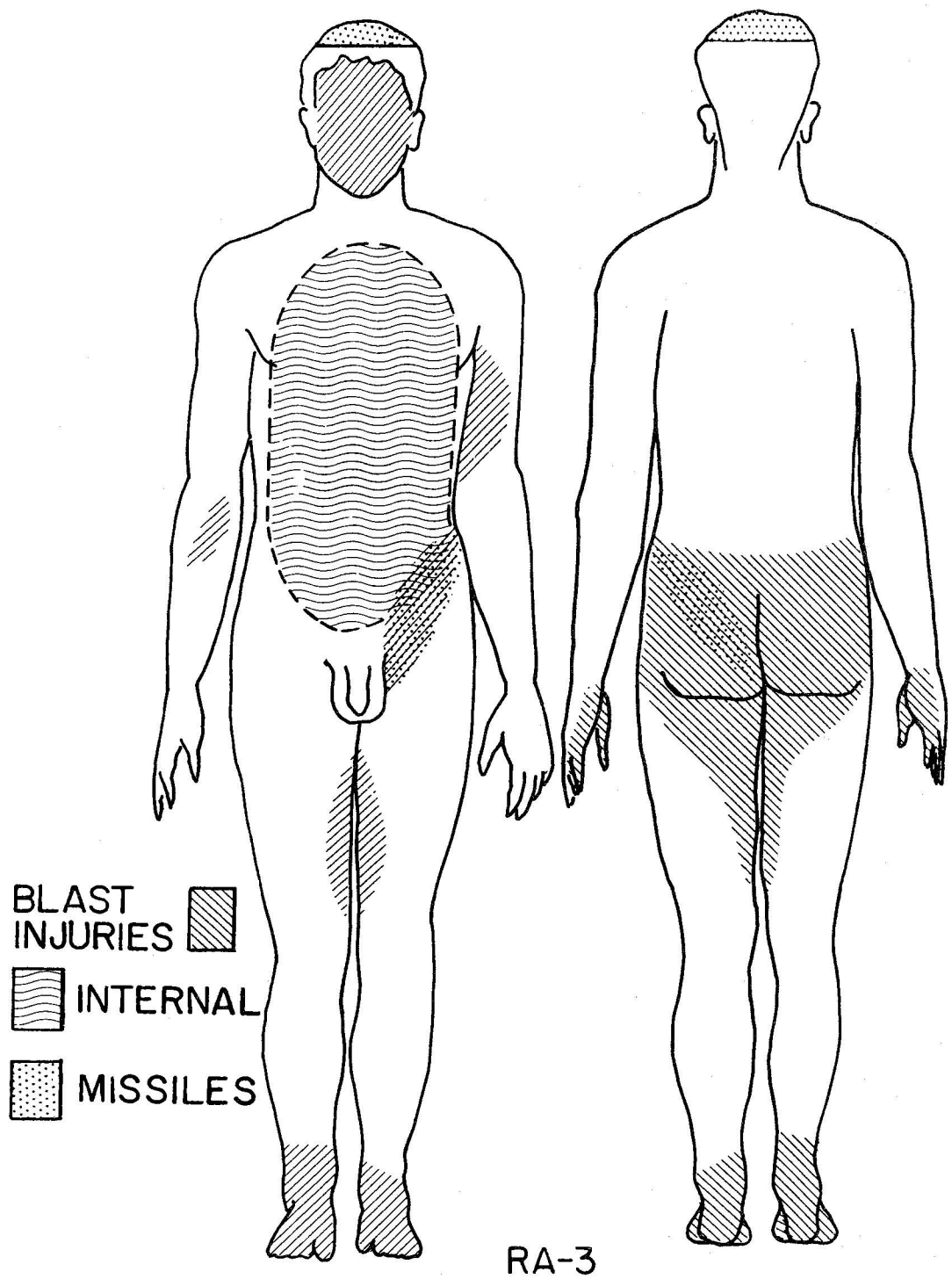


Fig. 5. Graphic summary of wounds of RA-3.

and kidneys formed one loose mass in the posterior of the abdominal cavity. All had a dusky parboiled appearance. There was remarkably little post-mortem odor and no evidence of decay, but neither the spleen nor pancreas could be found. In the process of twisting the upper half of the torso, all ribs were broken from their attachments to the vertebrae and freed from the muscles of the abdominal and thoracic walls (evidently by expanding gases).

Oral and Pharyngeal Mucous Membranes. Not examined.

Trachea and Main Bronchi. The trachea and main bronchi were torn from the upper part of the trachea and neck. They were colored dark red by hemolyzed (post-mortem) blood. The tracheobronchial lymph nodes were not recognizable.

Lungs. The lungs were collapsed and a dirty red color. They were not increased in weight.

Heart. The heart itself showed no external damage. It was not dissected. It was covered by blood and had the smoky, bluish red appearance of being partially parboiled.

Liver. The liver weighed about 600 grams. It was free from its diaphragmatic attachments but still attached to the stomach and intestines. Only the right half remained recognizable as normal dark red liver with a moderate parboiled hue. Shreds of what might have been the left lobe hung from it. No gallbladder was found.

Spleen. The spleen could not be found. Macerated, unrecognizable tissue was present. A search in the posterior of the abdominal cavity was not successful.

Pancreas. The pancreas was not recognizable.

Gastrointestinal Tract. The gastrointestinal tract appeared as that of a person dead for some time. The walls were hemorrhagic dusky red, opaque, cooked in appearance, and distended moderately with gas with the odor of fecal decay. It was remarkable, however, that there was very little odor emanating from these remains, although death had occurred approximately 1 week previous to this examination.

Adrenal Glands. The adrenal glands were not found.

Kidneys. Both kidneys had been stripped of their capsules. They were attached to the aorta, which had been stripped from its paravertebral attachments. The kidneys were the light tan color of serious terminal hemorrhage.

Genitourinary Tract. The urinary bladder and ureters were not found. The penis and testes, however, were normal in appearance except for hemorrhage between the capsule of the testes and tubules. The tubules teased apart easily. They appeared remarkably well preserved. The only sections made of this autopsy were of the testes, since the other organs showed such gross blast damage.

Brain. No attempt was made to salvage the remnants of the brain for study.

Gross Anatomical Diagnosis. Multiple blast injuries consisted of fractures of both ankles, both wrists, bones of the face, skull, and calvarium, left pelvis, hip, and femur, right femur, all ribs, and torsion fracture of cervical vertebrae and upper lumbar vertebrae; superficial burns of the inner aspects of the thighs, peritoneal surfaces, and abdominal and pleural organs; massive destruction of the muscles of the lower back, buttocks, and upper left thigh posteriorly; rupture of the abdominal wall, liver, spleen, diaphragm, lungs, aorta, and kidneys; missing spleen, pancreas, and adrenal glands; and tattoos ("C-bee" and dancing sailor girl).

3.3 Histologic Findings

3.3.1 RA-1

The pulmonary sections showed evidence of a long standing pneumoconiosis, which was still moderately active. In addition, there was acute congestion, edema, and desquamation of alveolar macrophages. Several venules showed increased numbers of leukocytes. The hilar lymph nodes had minimal anthracosis and fibrosis associated with pigment and diffusely deposited iron. The splenic arterioles were distorted by hyalinization and large deposits of PAS positive material resembling amyloid. This pathologic hyalinization

was also seen in the renal arterioles and Bowman's membrane. Except for a left shift in the myeloid series in the bone marrow, no other acute or chronic pathologic changes were noted.

Although many post-mortem changes were seen, these were remarkably few, in view of the 6 day interval between death and autopsy. Endothelium was seen free everywhere in the blood in the veins and in splenic sinuses. The mucosa of the bowel, unfortunately, was not examined but, in general, epithelial parenchyma was well preserved. The epithelial lining of thyroid acini was partially sloughed into the colloid; the epithelium of the renal collecting tubules was autolyzed, but that of the other tubules was not; the epithelium of the large pancreatic ducts was digested, but that of the small ducts was sloughed but stained well. Lymphocytes of the thymus, lymph nodes, and spleen stained well and appeared cytologically normal. The erythroid and myeloid cells in the bone marrow stained well. The entire germinative epithelium of the testicular tubules appeared normal, but chromatolysis and fading of cell outlines were seen among the testicular interstitial cells. Pancreatic acinar cells showed an irregular decrease in size, and their nuclei and cytoplasm were condensed. The cells of the islets, however, appeared normal. No autolytic changes in

the myocardial, hepatic, or adrenal parenchyma were seen.

3.3.2 RA-2

The organs of this man were also remarkably well preserved histologically. Some previously existing pathologic changes were observable such as moderate hypertrophy of myocardial fibers and their nuclei, mild chronic interstitial pneumonitis, and pulmonary and hilar nodal anthracosis. Evidence of blast damage was found in traumatic emphysema and atelectasis of the lungs and hemorrhagic destruction of the thymus and liver. Although post-mortem digestion was minimal in most organs, it was extensive in the pancreas, kidneys, and prostate in contrast to RA-1. All renal tubules were recognizable but severely altered by autolysis. The pancreas was recognizable chiefly by the outline of glands which were otherwise amorphous and failed to stain with eosin. The prostatic glandular epithelium had all sloughed into the lumina, but again the preservation of the germinal epithelium of the testis was excellent. Only a few Leydig cells showed autolysis and fading.

3.3.3 RA-3

Only sections of the testis were made. The other organs were extensively damaged by blast, and dissection beyond that

required for identification was considered unwarranted because of the radiation hazard. In retrospect, more sections should have been obtained in order to investigate their state of post-mortem preservation. The section of testis (Fig. 6) showed preserved mitotic figures, sperme in the spermatocytes, and, in general, normal cytology of all cells except the spermatogonia, which were almost all densely pyknotic. The cells of Leydig were all autolyzed and not recognizable.

3.4 Causes of Death

The deaths of the 3 men were individually quite different, even though they were in a small area which was subjected to a severe blast for a short time. RA-1 died as the result of hemorrhage from the avulsion of his left hand and the right side of his face, along with the intracranial subdural hemorrhage that followed a lacerating blow to the top of his head. He lived a short time (about 2 hours) unconscious and in deep shock after the explosion. RA-2 died the instant he struck a flat surface that fractured his chest and drove a rib through his heart. External hemorrhage from his blast wounds was post mortem. RA-3 died instantaneously from the destruction of his viscera by rapidly expanding gases that penetrated his abdominal cavity along with a heavy missile.

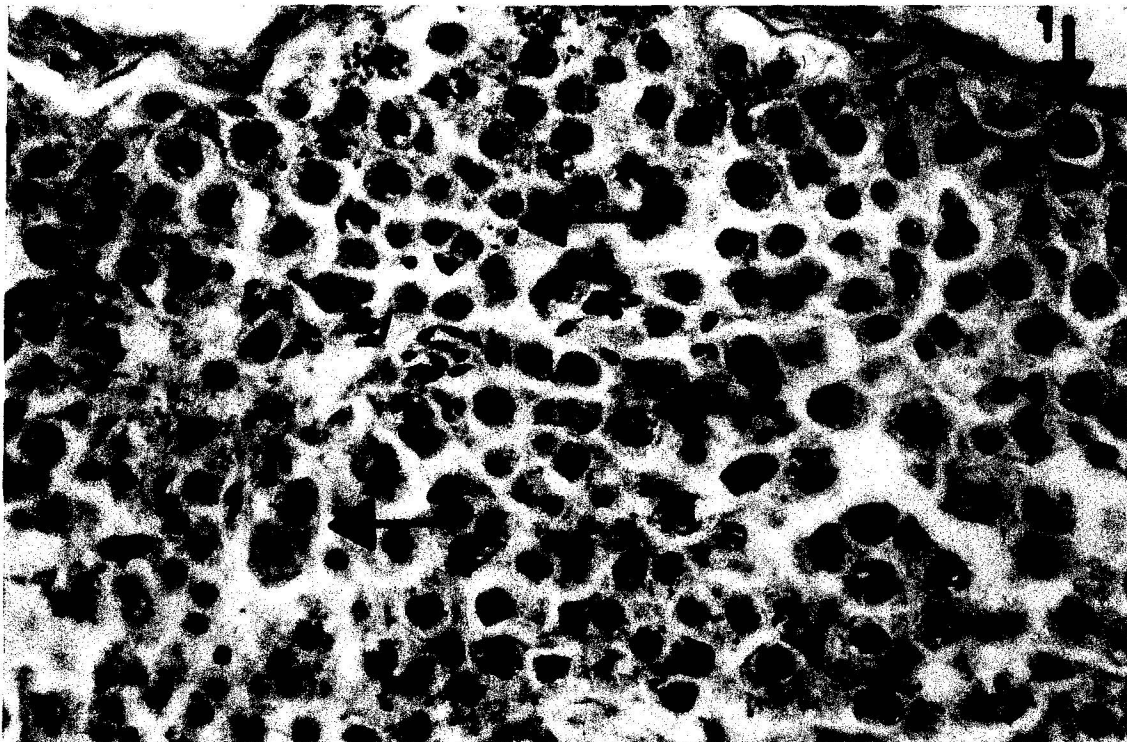


Fig. 6. Photomicrograph (X 700) of a testicular tubule from RA-3, formalin-fixed 9 days after death. Post-mortem autolysis is minimal. Arrows point to (1) pyknotic spermatogonia; (2) normal appearing spermatids and sperm; (3) normal spireme in a spermatocyte; and (4) a recently completed but pyknotic mitosis.

3.5 Biochemical Findings

Samples were obtained for chemical estimation of fast neutron dose from the hair removed from the head and pubis of these men. Previous studies (3) had shown that quantitative isolation of radiophosphorus from hair exposed to fast neutrons afforded an excellent means of estimating total neutron doses of known energy distribution. In the present investigation, heavy contamination of the samples by fission products imposed the problem of separating P^{32} activity from large amounts of other beta and gamma radioactivity. The samples were handled preliminarily in a hot cell, where they were washed successively with detergents, water, and organic solvents. Residual radioactivity was then 30 r/hr. They were then decontaminated further chemically (4) and the phosphorus ultimately isolated after a series of repetitive precipitations as magnesium ammonium phosphate hexahydrate, which was then radioassayed.

The assumption was made that all P^{32} activity in the samples was the result of fast neutron activation. The results of this investigation, which are summarized in Table 3, showed that a critical excursion of the order of 3×10^{18} total fissions had occurred at the time of these fatalities. These data suggest that all 3 men received large neutron doses to the head. The amount each man appeared to have

TABLE 3. NEUTRON DOSIMETRY BASED UPON RADIOCHEMICAL
PHOSPHORUS³² ANALYSES OF HAIR SAMPLES

Sample No.	Source	Flux Detected by Sulfur (n/cm ²)	Dose > 2.5 Mev (rads)	Deduced Position
RA-1	Head	2.04×10^{12}	7.81×10^3	Partially shielded
	Pubis	8.27×10^9	3.17×10^1	Shielded
RA-2	Head	2.84×10^{13}	1.08×10^5	Exposed
	Pubis	4.85×10^{11}	1.86×10^3	Partially shielded
RA-3	Head	9.26×10^{12}	3.54×10^4	Exposed

* 3×10^{18} total fissions, based on the average flux detected by all samples except the pubis from RA-1, and assuming an energy distribution comparable to the Los Alamos Omega West Reactor.

received corresponded well with the reconstruction of the scene of the accident based upon the blast injuries. Since an indeterminate amount of the isolated P^{32} activity could have resulted from contamination by phosphates in reactor water previously activated during operation of the reactor, these neutron dosage estimates may be fallacious. However, they are certainly useful in positioning the men in relation to the source of radioactivity and its explosion.

3.6 Reconstruction of Positions of the Men at Time of the Accident

Study of the nature, distribution, and severity of the blast wounds of these men enabled a reconstruction of their most likely positions and relationships to one another and to the blast at the time the accident occurred (Figs. 7, 8, and 9). RA-1 was obviously the most distant because he received the fewest and least severe blast injuries and was the only one wounded by flying missiles from the reactor shield. He was most likely standing with his left leg and hand nearest the reactor, facing the other 2 men. His right hand and arm were away from the blast, either behind him or behind an object he was carrying into the area (Figs. 8 and 9). RA-2 and RA-3 were both blasted severely and must, therefore, have been upon the reactor top. The



Fig. 7. Mock-up of SL-1 reactor top used to position subjects in order to reconstruct the scene at the time of the accident. The C-clamp identifies port No. 1; the bell housing covers port No. 5.




Fig. 8. Simplest positions for all 3 men that seem to satisfy the requirements for causing their blast wounds. The numbers identify them as RA-1, RA-2, and RA-3.



Fig. 9. Simplest positions for all 3 men that seem to satisfy the requirements for causing their blast wounds at 90° counterclockwise from positions given in Fig. 8.

fact that the right foot of RA-2 was not injured, while his lower left leg and foot were demolished, seemed to indicate that his right leg was to the outside or adjacent to a reactor port that did not explode, while his left leg was in the midst of the blast. He was in a standing position facing slightly outward, since he was struck chiefly from below and behind so that his buttocks, left hip and upper leg, and back of right knee were destroyed (Fig. 9). The dilemma of blast injury to his face (on the side of his body uninjured by blast) can be resolved by turning his head to look back over his shoulder under an outstretched arm or between his legs. His uninjured hands must have been up and out of the vortex of the blast or protected by his body.

The multiple severe blast wounds of RA-3 indicated that he was the closest in and right over the principal upward force. His wounded ankles, thighs, hands, face, and head appeared at first glance to be randomly distributed and widely separated from one another by large comparatively unharmed areas. That they all could have occurred simultaneously in a small confined area of rapidly expanding forces is seen when a man is placed in a squatting position with his head bent down as he watches what he is doing with his hands inside his ankles (Figs. 8 and 9). This position

appears to satisfy not only the requirements of his external injuries but shows how the blast could also have penetrated his abdomen and simultaneously destroyed his viscera. While this reconstructed scene probably is not exactly correct, it appears to be sufficiently well fixed by the nature of the wounds to warrant the important conclusion that these men were carrying out their assigned task in accordance with the standard operating procedures in which they had been trained.

CHAPTER 4

SUMMARY

A 9 man team, comprised of 1 pathologist, 2 physicians, 1 radiobiologist, and 5 health physicists, decontaminated and autopsied 3 men heavily contaminated with radioactive materials. Although surface level exposure rates were in excess of 500 r at the beginning of the operation, final radiation levels (with 1/8 to 3/4 in. lead) were below 650 mr/hr. None of the personnel involved received in excess of 4 r. The autopsies showed that 2 of the men died immediately and 1 within 2 hours from the primary and secondary wounds they received. The distribution and nature of these wounds, along with chemical dosimetric studies of hair samples, enabled a logical reconstruction of the scene at the time of the explosion, which led to the conclusion that the explosion occurred while standard operating procedures were being followed.

This investigation showed that complete autopsies can

be done safely upon men emitting large amounts of gamma activity and that the autopsy procedures themselves can be a material aid in physical decontamination of such bodies and in preparation for their burial. In addition, the following recommendations were derived from this experience for the design of a room for decontamination of radioactive dead bodies:

1. Sinks large enough to hold a human body are absolutely necessary; this room should be equipped with remotely operated water and drains which cannot be plugged by bodies or debris.

2. A portable lead shield with a lead-glass viewing area should be provided, and arm ports should be available for positioning in front of the sink.

3. Vertical pits in the floor of the room (6 feet deep and 3 feet wide) could be used to shield bodies not being decontaminated and to hold heavily contaminated materials for future disposal.

4. A remotely controlled overhead crane should be available for lifting and moving bodies, which should be brought to the facility with a rope sling under the arms and about the chest. These slings should have quick connect-disconnects.

5. If contamination by plutonium is conceivable, the

room should have airlock entrances and exits.

6. The room should be uncluttered and easily cleanable. Large trucks should be able to enter it.

7. Lead casks should be designed no deeper than necessary to hold and shield human bodies to expedite immediate transportation. This cask should have drains operable from the outside.

8. Shielded deep-freeze units should be available and large enough to store whole bodies and biologic samples.

9. Studies of decontamination of experimental animals should be made of various decontamination agents, collodion and strippable agents, and perhaps ultrasonic cleansing procedures.

The following recommendations concerning chemical dosimetry were made:

1. Samples should be taken under conditions as close to those extant at time of the incident as possible and before decontamination procedures are instituted. If a living patient is involved, the sampling would have to be done immediately, since it would not justify a delay in decontamination, and appropriate personnel (i.e., first-aid and rescue people) should be aware of sampling techniques, if dose information from conventional dosimetry systems is not available.

2. Appropriate control samples should be obtained as swipes from the immediate area.

3. Additional analytical materials, gold fillings, silver-amalgam fillings, etc., should be saved.

4. Short-lived emitters, such as 17 hour Zr^{95} and Mo^{99} , should take precedence over phosphorus measurements.

REFERENCES

- (1) SL-1 Explosion Kills 3; Cause and Significance Still Unclear, *Nucleonics* 19(2), 17-23 (February 1961).
- (2) Safe Handling of Bodies Containing Radioactive Isotopes (A Guide for Surgeons, Pathologists, and Funeral Directors), National Bureau of Standards Handbook No. 65, Superintendent of Documents, Washington 25, D. C. (July 10, 1958).
- (3) D. F. Petersen, V. E. Mitchell, and W. H. Langham, Estimation of Fast Neutron Doses in Man, *Health Phys.* (in press).
- (4) D. F. Petersen and R. J. Prestwood, Estimation of Fast Neutron Doses in Man by Measurement of the $S^{32}(n,p)P^{32}$ Reaction in Hair. II. Phosphorus³² Measurements in Samples Heavily Contaminated with Fission Products, in manuscript.

